

# Intra-abdominal Abscess Drainage from Douglas Pouch to Vagina after Liposuction

✉ Gülseren Polat<sup>1</sup>, ✉ Zeynep Aybikem Sağlam<sup>2</sup>

<sup>1</sup>Istanbul Gelişim University, Vocational School of Health Services, Department of Obstetrics and Gynecology, İstanbul, Turkey

<sup>2</sup>Istanbul Medipol University Faculty of Medicine, Department of Obstetrics and Gynaecology, İstanbul, Turkey

## What is known on this subject?

The increasing demands of women have led to the development of different methods in the field of gynecology.

## What this case report adds?

This report aims to raise awareness about a rare, hence, severe complication of female cosmetic surgery.

## ABSTRACT

Female genital cosmetic surgery covers procedures performed to correct or change the genital anatomy without a specific organic condition or disease. The increasing demands in the last decade led to the improvement of methods in cosmetic gynecology. This report aims to raise awareness about a rare hence severe complication of female cosmetic surgery. The case of an abdominal abscess caused by ileal perforation that occurred during abdominal liposuction for aesthetic surgery, and drained from the Douglas pouch to the vagina is presented. Intestinal perforation may rarely occur after abdominal liposuction in patients who have previously had an abdominal operation or have abdominal diastasis, as in our patient. In the advancing field of female genital cosmetic surgery, the application of liposuction for monsplasty or autologous fat grafting to the labia majora can present significant morbidity and mortality complications. Documenting these complications in the literature will disseminate knowledge. Awareness of risk factors and complications in the planning and application of operations can greatly support cosmetic gynecologists in improving patient safety.

**Keywords:** Cosmetic gynecology, intra-abdominal abscess, liposuction, monsplasty

## Introduction

Female genital cosmetic surgery covers procedures performed to correct or change the genital anatomy without a specific organic problem or disease. Achieving the aesthetic goals that women desire regarding their genitalia positively affects their reproductive, sexual, and emotional health. A woman who is content with her own body is happy, self-confident, and productive. The increasing

demands of women in the last decade have led to the development of different methods in the field of gynecology.


Liposuction of the mons pubis for aesthetic and functional purposes, or abdominal liposuction for autologous fat grafting to the labia majora, is a new area of operation in cosmetic gynecology. As they are reconstructive surgeries that are not performed for medical indications, it is believed that there is still insufficient scientific

**Corresponding Author:** Gülseren Polat, MD, İstanbul Gelişim University, Vocational School of Health Services, Department of Obstetrics and Gynecology, İstanbul, Turkey

**E-mail:** gulserenpolat@gmail.com **ORCID ID:** orcid.org/0000-0002-5654-7967

**Received:** 11.09.2024 **Accepted:** 31.01.2025 **Epub:** 04.06.2025

**Cite this article as:** Polat G, Sağlam ZA. Intra-abdominal abscess drainage from douglas pouch to vagina after liposuction. Cam and Sakura Med J. [Epub Ahead of Print].



evidence regarding the indications, risks, safety, efficacy, and applications of monsplasty and labioplasty.

We present the case of an abdominal abscess caused by ileal perforation that occurred during abdominal liposuction for aesthetic surgery, and drained from Douglas pouch to the vagina. This case aims to raise awareness about a rare complication that may occur in female cosmetic surgery.

## Case Report

A 38-year-old patient, who is gravida 2, para 2, with a prior section, and who underwent liposuction and abdominoplasty 5 days prior at a different hospital, had a computed tomography (CT) scan due to complaints of gradually increasing abdominal pain, fever, and no gas or stool discharge. She was referred to our hospital with the preliminary diagnosis of an ileum perforation. When the patient presented to the surgery department, she was diagnosed with acute abdomen due to her symptoms: abdominal pain, tenderness, and positive rebound and defense during her abdominal examination. Her vital signs were within normal limits: blood pressure was 120/80 mmHg, heart rate was 78 beats per minute, respiratory rate was 18 breaths per minute, and body temperature was 36.9 °C. Her laboratory results were as follows: leukocyte count: 23,550/ $\mu$ L, hemoglobin: 8.8 g/dL, C-reactive protein: 173 mg/L, international normalized ratio: 1.29, serum creatinine: 0.4 mg/dL, and procalcitonin: 1.78 ng/mL.

The patient underwent exploratory laparotomy at our clinic. During the laparotomy, widespread necrosis and intestinal contents were observed in the area extending to the pelvis. The punctate perforation areas were observed when the small intestine was dissected and closed with primary repair. The abdomen was irrigated with physiological saline. A drain was placed in the pelvis, and antibiotic treatment was initiated after consulting with the infectious diseases department. Body fluid culture grew *Enterococcus faecalis* and *Candida albicans*. The patient had a fever on the 3<sup>rd</sup> postoperative day and underwent a gynecological consultation due to vaginal discharge. During the gynecological examination, a culture was taken from the discharge. Speculum examination revealed pus emerging from the posterior fornix. During manual vaginal examination, a 2 cm laceration area was felt in the posterior fornix. The vagina was irrigated with physiological saline. Repeated CT scan showed localized effusion in the abdomen and thickening in the peritoneum. Collections of small locules in the mesentery were also observed. Results from the abdominal drainage catheter were obtained. The posterior fornix laceration closed spontaneously on the 16<sup>th</sup>

postoperative day, and the patient was discharged with full recovery on the 22<sup>nd</sup> postoperative day (Figures 1, 2).

## Discussion

Cosmetic liposuction, which is performed to change the contour or shape of the body, has been advancing rapidly and becoming widespread over the last 50 years (1). It is the most frequently performed procedure by plastic surgeons in Germany and Brazil and the second most common surgery in the world (2,3). Complications encountered after cosmetic liposuction are generally mild. Since it is considered a minimally invasive, safe, and minor surgery, the possibility of serious morbidity or mortality is not taken into account.

In female cosmetic genital surgery, abdominal liposuction is applied to the labia major and vagina for fat filling, or to the pubic region for monsplasty. Complications such as pain, bleeding, infection, scar formation, skin collapse, seroma, adhesions, change in sensation, dyspareunia, change in sexual pleasure, abnormal hair growth, and the need for re-operation may occur as a result of these procedures. Rarely, serious complications such as intestinal perforation, necrotizing fasciitis, and embolism may occur after abdominal liposuction, as in our case (4,5). The frequency of these complications may increase with the increase in liposuction volume. It has been published that during the liposuction procedure performed in a center providing outpatient treatment, aspiration ranges from 0.5 to 8 liters, with an average of 2.6 liters (4). In our practice, a much lesser amount of 20-100 cc of liposuction is applied. The reported incidence of bowel and internal organ perforation during liposuction, as in our case, is <0.1 percent (4). When these cases were evaluated, it was seen that the patients had previous abdominal surgery or had abdominal diastasis. To prevent these complications, patients' medical history must be adequately documented, and physical examination must be performed carefully for abdominal diastasis before the operation. It should not be forgotten that liposuction is a surgical procedure and should be performed under especially aseptic conditions. Using inadequate depth during the suction technique may cause destruction of the subcutaneous vascular system and skin necrosis. All liposuction patients should be re-examined within 24 hours after the procedure (6).

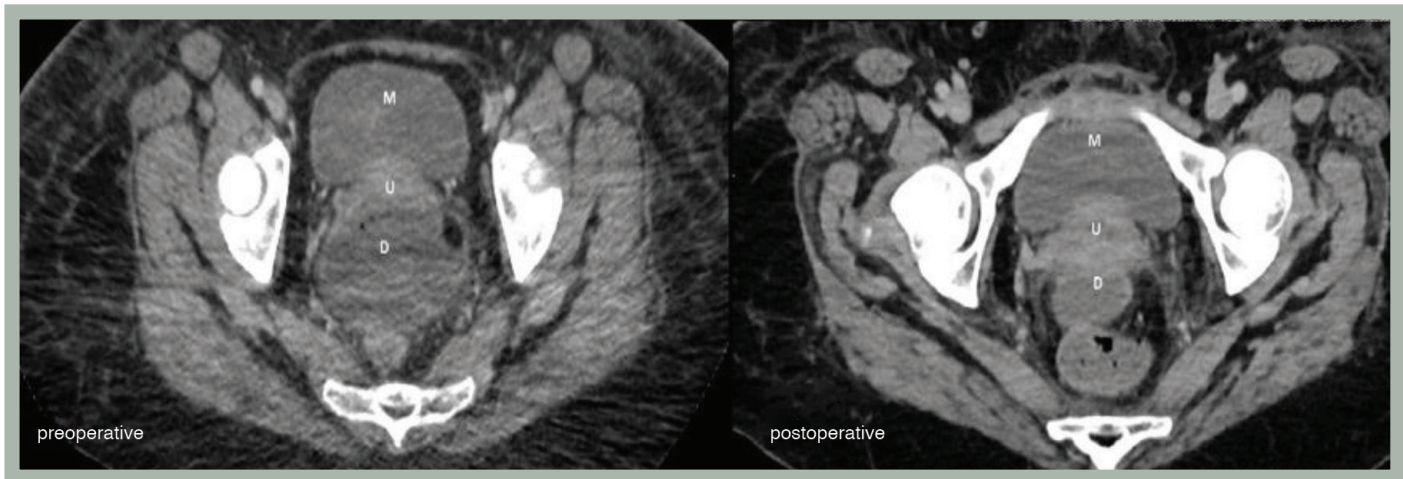
Genital cosmetic procedures are profitable and there is growing patient interest and demand. Patients expect cosmetic changes in their genitalia with easily applicable, safe and minimally complicated procedures. Before the operation, the patient's expectations and the physical medical consequences should be discussed, and patients should be



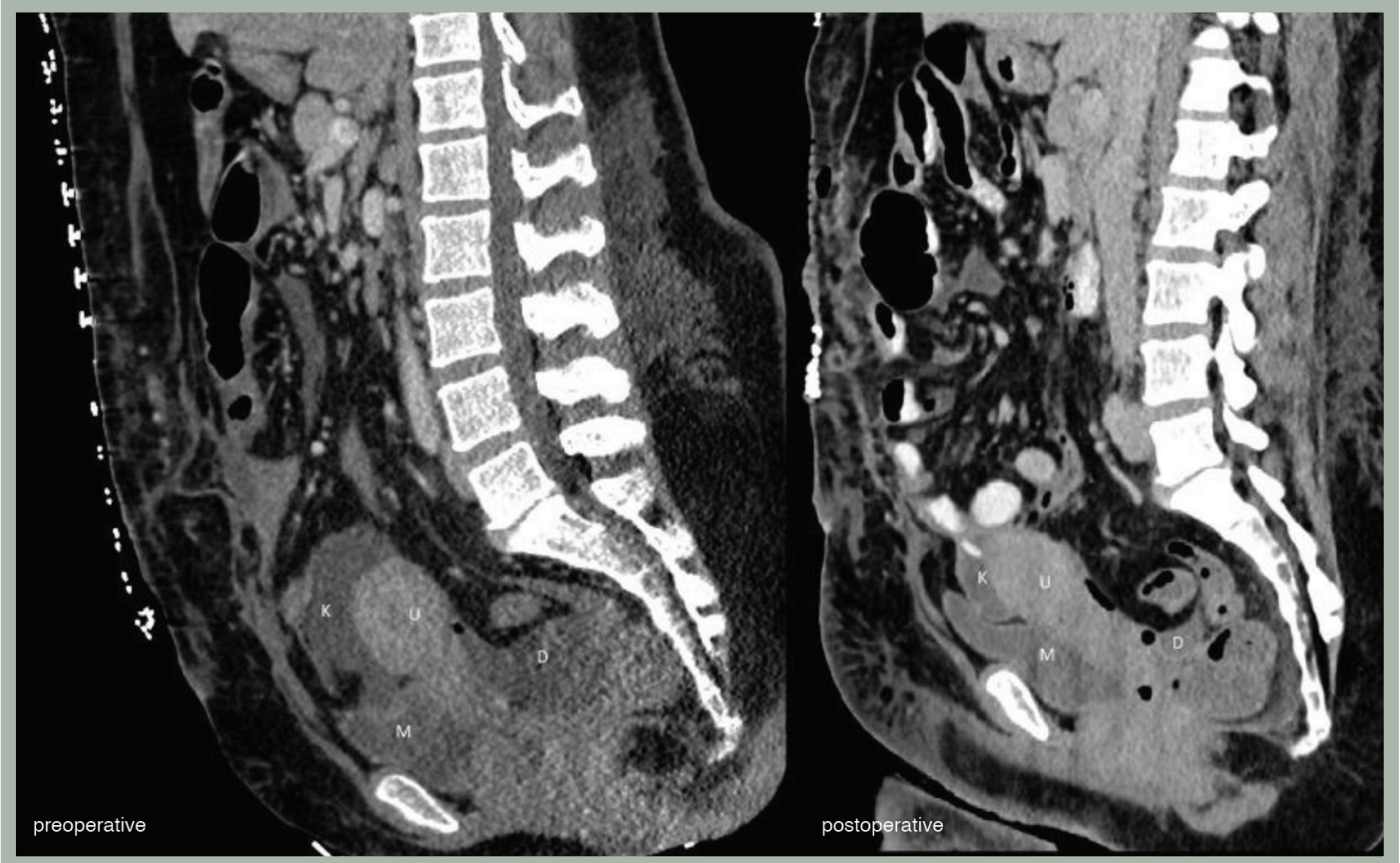informed. Educating the patients is necessary to assist them in making conscious decisions. Consequences that exceed patient expectations may affect their physical and psychological well-being.

We have insufficient data regarding the early or late complications and risks of liposuction application for monsplasty or labia major autologous fat grafting. In cosmetic surgical procedures, data analysis and evaluation of results

are inadequate due to very limited or incomplete patient records (7). Survey results regarding patient satisfaction or improvement in sexual function without a comparison group should be interpreted with caution. Currently, there is no standardized training program or specific training area in the field of female cosmetic genital surgery. These operations are conducted by inexperienced individuals who are trained through courses organized by experienced professionals in this



**Figure 1.** Transverse section demonstrating preoperative and postoperative views



**Figure 2.** Sagittal section demonstrating preoperative and postoperative views

field. The lack of restrictive legal rules and adequate education services are important shortcomings. In its committee opinion updated in 2020, the American College of Obstetricians and Gynecologists recommended that patients be informed about the lack of sufficient data on the indications, risks, safety, and effectiveness of female genital cosmetic operations (8). The long-term effects of aging, menopause, and natural anatomical and physiological changes due to pregnancy on those who undergo cosmetic surgery are topics that will be discussed.

Considering this rapidly developing field, performing liposuction for monsoplasty or autologous fat grafting to labia majora may cause severe fatal complications. Documenting these complications in the literature will enhance and share knowledge. Awareness of risk factors and complications in the planning and application of operations can greatly support cosmetic gynecologists in improving patient safety.

### Ethics

**Informed Consent:** Written informed consent was obtained from the patient for the publication of this case report and any accompanying images.

### Footnotes

### Authorship Contributions

Surgical and Medical Practices: G.P., Concept: G.P., Design: G.P., Data Collection or Processing: G.P., Z.A.S., Analysis or Interpretation: G.P., Z.A.S., Literature Search: G.P., Z.A.S., Writing: G.P., Z.A.S.

**Conflict of Interest:** No conflict of interest was declared by the authors.

**Financial Disclosure:** The authors declared that this study received no financial support.

## REFERENCES

1. Bellini E, Grieco MP, Raposio E. A journey through liposuction and liposculture: review. *Ann Med Surg (Lond)*. 2017;24:53-60.
2. Lehnhardt M, Homann HH, Daigeler A, Hauser J, Palka P, Steinau HU. Major and lethal complications of liposuction: a review of 72 cases in Germany between 1998 and 2002. *Plast Reconstr Surg*. 2008;121:396e-403e.
3. Pereira-Netto D, Montano-Pedroso JC, Aider ALES, Marson WL, Ferreira LM. Laser-assisted liposuction (LAL) versus traditional liposuction: systematic review. *Aesthetic Plast Surg*. 2018;42:376-383.
4. Kaoutzanis C, Gupta V, Winocour J, et al. Cosmetic liposuction: preoperative risk factors, major complication rates, and safety of combined procedures. *Aesthet Surg J*. 2017;37:680-694.
5. Sharma D, Dalencourt G, Bitterly T, Benotti PN. Small intestinal perforation and necrotizing fasciitis after abdominal liposuction. *Aesthetic Plast Surg*. 2006;30:712-716.
6. Taha AA, Tahseen H. Spreading awareness: bowel perforation with liposuction. *Plast Reconstr Surg Glob Open*. 2020;8:e2715.
7. Barillo DJ, Cancio LC, Kim SH, Shirani KZ, Goodwin CW. Fatal and near-fatal complications of liposuction. *South Med J*. 1998;91:487-492.
8. American College of Obstetricians and Gynecologists (ACOG). Elective Female Genital Cosmetic Surgery Committee Opinion. 2020; number 795. Available from: <https://www.acog.org/clinical/clinical-guidance/committee-opinion/articles/2020/01/elective-female-genital-cosmetic-surgery>